

# Your Practice Online

P R E S E N T S

## Hip Anatomy

Multimedia Health Education

### *Disclaimer*

This movie is educational resource only and should not be used to make a decision on hip resurfacing or about arthritis management. All decisions about hip resurfacing and management of arthritis must be made in conjunction with your surgeon or a licensed healthcare provider.

#### **Australia**

Dr. Prem Lobo  
G.P.O Box No.635  
SYDNEY NSW- 2001

Phone: 1 800 883 260  
Fax: +61 2 9475 1036  
Email: [info@yourpracticeonline.com.au](mailto:info@yourpracticeonline.com.au)

#### **USA**

Holly Edmonds RN, CLNC  
1006 Triple Crown Drive  
Indian Trail, NC 28079

Toll Free: 1 877 388 8569 (Toll Free)  
Fax: 1 718 785 9593  
Email: [info@yourpracticeonline.net](mailto:info@yourpracticeonline.net)

#### **New Zealand**

Greg Eden  
P O Box 17 340 Greenlane  
Auckland 1130

Phone: +09 974 9839  
Fax: +64 9 634 6282  
Email: [info@yourpracticeonline.co.nz](mailto:info@yourpracticeonline.co.nz)

[WWW.YOURPRACTICEONLINE.NET](http://WWW.YOURPRACTICEONLINE.NET)

Your Practice Online

## MULTIMEDIA HEALTH EDUCATION MANUAL

### TABLE OF CONTENTS

SECTION	CONTENT
<b>1. Normal Hip</b>	
a. Hip Bone	
b. Fibrous Tissue	
<b>2. Arteries &amp; Nerves</b>	
<b>3. Movements</b>	

### Introduction

The hip is a ball and socket joint that allows the upper leg to move front to back and side to side. The hip is the largest weight bearing joint in the body, it is surrounded by strong ligaments and muscles.

### Hip Bone

The hipbone is a large, flattened, irregularly shaped bone, constricted in the centre and expanded above and below.

(Refer fig.1)

- Ilium
- Pubis
- Ischium
- Acetabulum

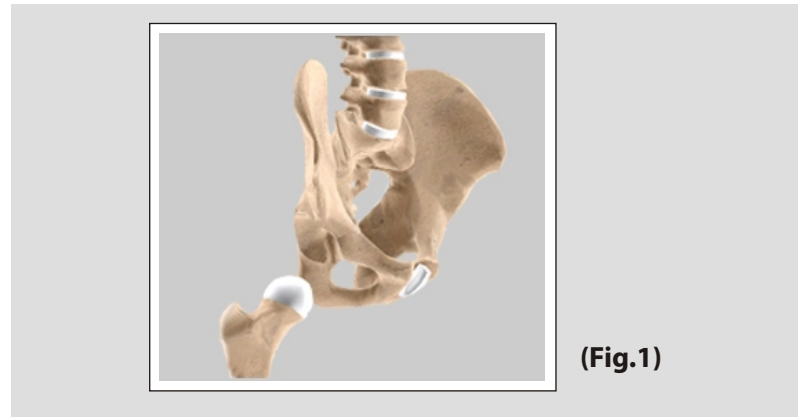
It consists of three parts, the ilium, ischium, and pubis, which are distinct from each other in the young subject, but are fused in the adult; the union of the three parts takes place in and around a large cup-shaped articular cavity, the acetabulum, which is situated near the middle of the outer surface of the bone.

### Ilium

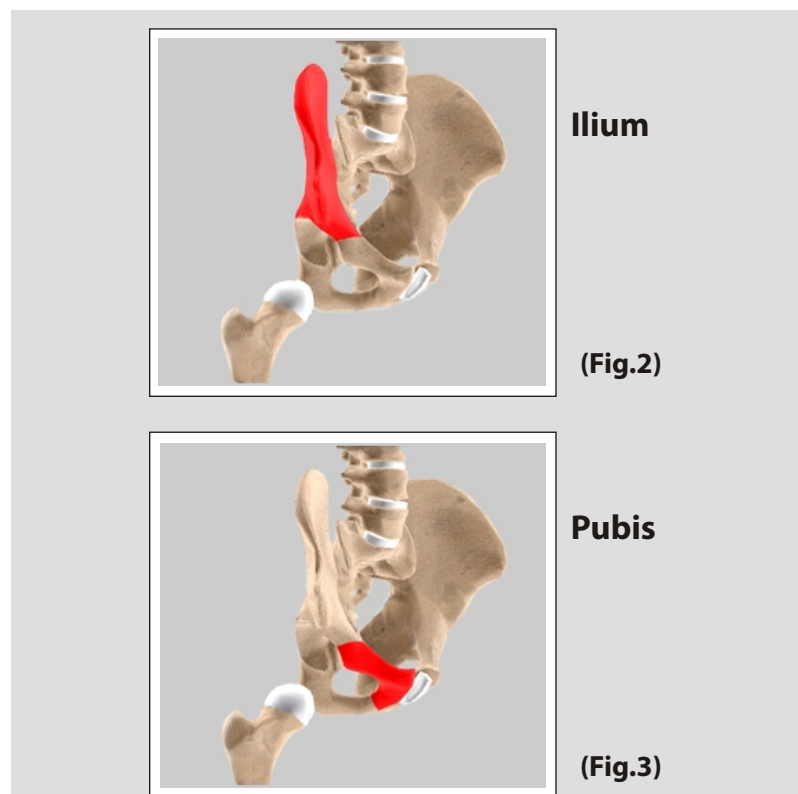
(Refer fig. 2)

### Pubis

(Refer fig. 3)

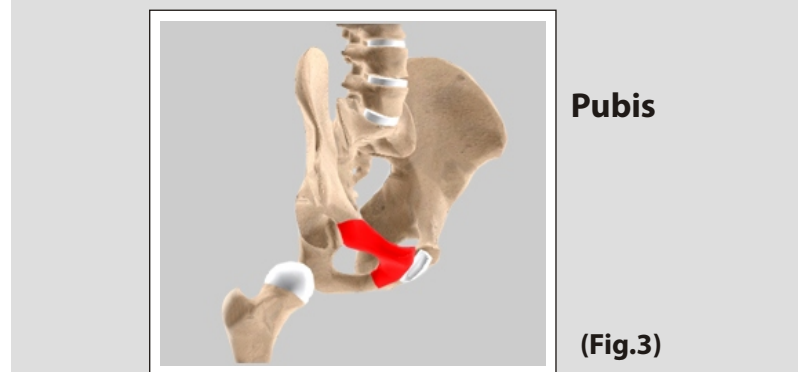


(Fig.1)



Ilium

(Fig.2)



Pubis

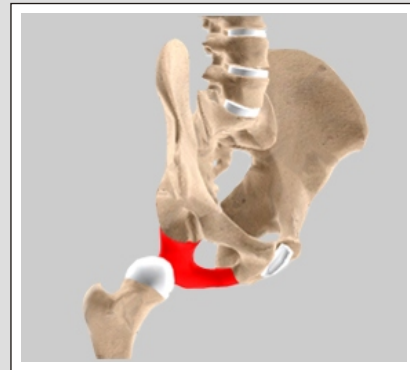
(Fig.3)

### Unit:1

### Normal Hip

#### Ischium

(Refer fig. 4)

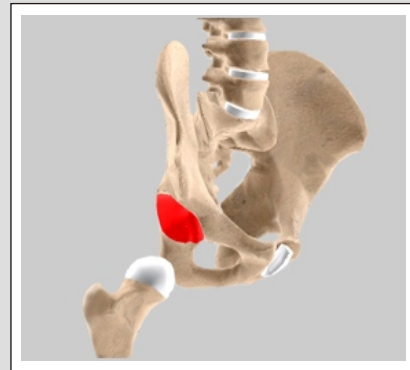


**Ischium**

(Fig.4)

#### Acetabulum

(Refer fig. 5)



**Acetabulum**

(Fig. 5)

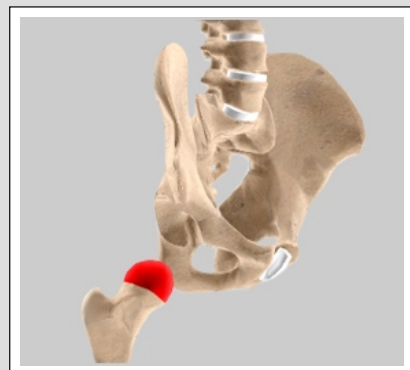
#### Femur

The femur is the longest bone in the skeleton. It joins to the pelvis (acetabulum) to form the hip joint. The upper part is composed of Femoral head, Femoral Neck, Greater and Lesser trochanters.

- Head
- Neck
- Greater trochanter
- Lesser trochanter

#### Head

(Refer fig. 6)

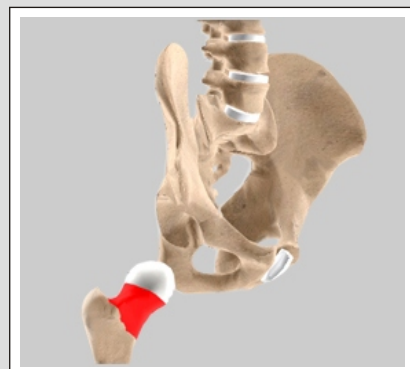


**Head**

(Fig. 6)

#### Neck

(Refer fig. 7)



**Neck**

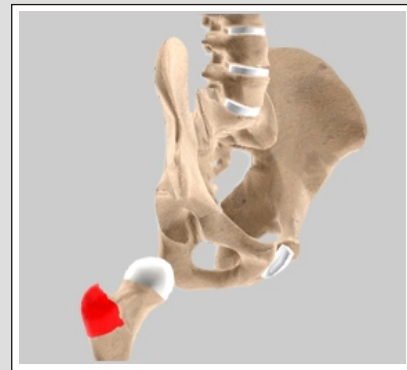
(Fig. 7)

### Unit:1

### Normal Hip

#### Greater trochanter

(Refer fig. 8)

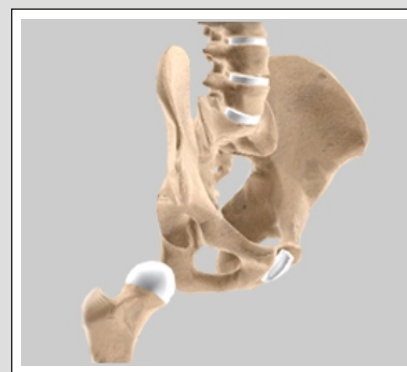

**Greater trochanter**

(Fig. 8)

#### Lesser trochanter

(Refer fig. 9)



**Lesser trochanter**

(Fig. 9)

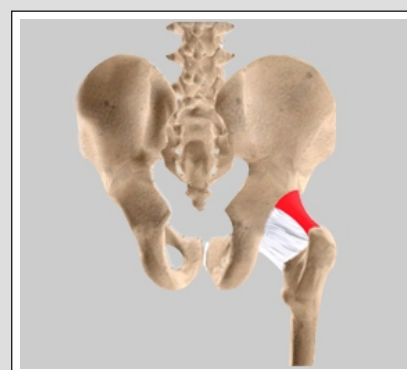
#### Fibrous Tissue

The movements of the hip are very extensive, and consist of Flexion, Extension, Adduction, Abduction, Circumduction and Rotation. The hip-joint presents a very striking contrast to the shoulder-joint in that it is more complete mechanical arrangements for its security and for the limitation of its movements.

- Iliofemoral ligament
- Pubofemoral ligament
- Ischiofemoral ligament
- Ligamentum Teres
- Acetabular Labrum

#### Iliofemoral ligament

(Refer fig. 10)



**Iliofemoral ligament**

(Fig. 10)

### Unit:1

### Normal Hip

#### Pubofemoral ligament

*(Refer fig. 11)*

#### Ischiofemoral ligament

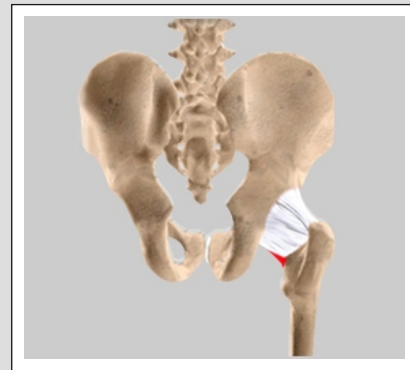
*(Refer fig. 12)*

#### Ligamentum Teres

*(Refer fig. 13)*

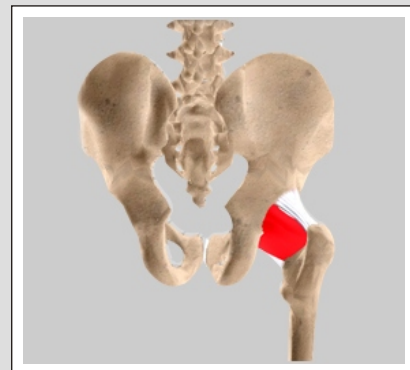
#### Acetabular Labrum

*(Refer fig. 14)*



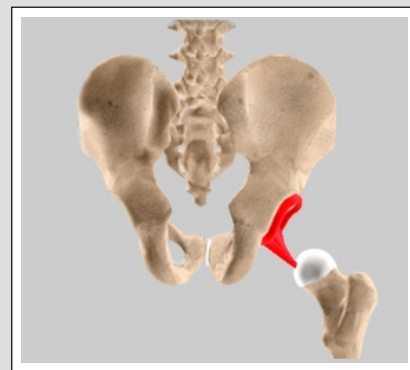
**Pubofemoral ligament**

**(Fig. 11)**



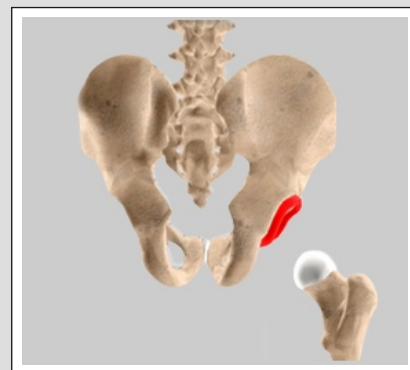
**Ischiofemoral ligament**

**(Fig. 12)**



**Ligamentum Teres**

**(Fig. 13)**



**Acetabular Labrum**

**(Fig. 14)**

### Arteries

The arteries supplying the hip joint are derived from the obturator, medial femoral circumflex, and superior and inferior gluteals. The nerves are articular branches from the sacral plexus, sciatic, obturator, accessory obturator, and a filament from the branch of the femoral supplying the Rectus femoris.

### Hilton's Law:

A nerve trunk which supplies a joint also supplies the muscles of the joint and the skin over the insertions of such muscles.

### Movements

The movements of the hip are very extensive, and consist of Flexion, Extension, Adduction, Abduction, Circumduction and Rotation. The hip-joint presents a very striking contrast to the shoulder-joint in that it is more complete mechanical arrangements for its security and for the limitation of its movements.

- Flexion & extension
- Abduction & adduction
- Circumduction
- Rotation

### Flexion & extension

(Refer fig. 15)

- ▶ Red Line is flexion (lifting the leg)
- ▶ Blue is extension (putting it back)

### Abduction & adduction

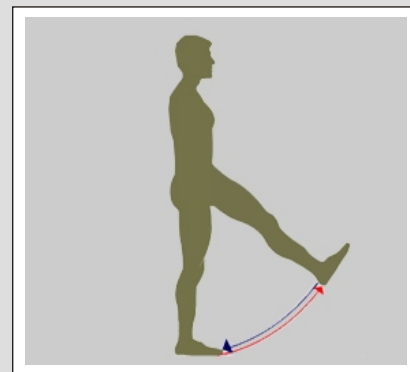
(Refer fig. 16)

- ▶ Adduction & abduction in flexion Abduction is away from the midline and the adduction is towards the midline
- ▶ Abduction & Adduction in extension

### Circumduction

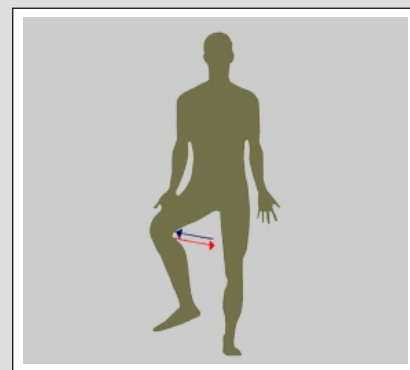
(Refer fig. 17)

- ▶ The circular movement of a limb such that the distal end of the limb delineates an arc.



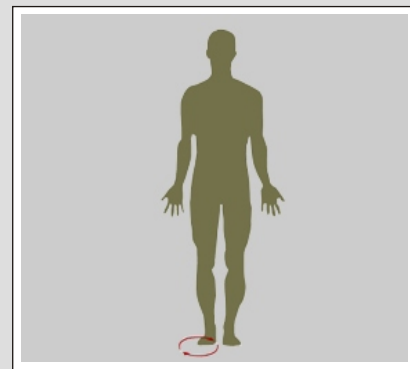
**Flexion & extension**

(Fig. 15)



**Abduction & adduction**

(Fig. 16)



**Circumduction**

(Fig. 17)



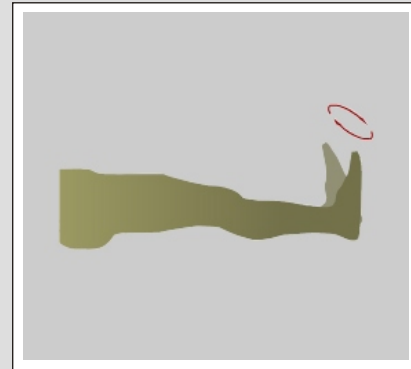
### Unit: 3

### Movements

#### Rotation

*(Refer fig. 18)*

- ▶ Internal rotation towards the inside.



#### Rotation

**(Fig. 18)**

### Disclaimer

Although every effort has been made to explain the complications there will be complications that may not have been specifically mentioned. A good knowledge of this operation will make the stress of undertaking the operation easier for you to bear. The decision to proceed with the surgery is made because the advantages of surgery outweigh the potential disadvantages. It is important that you are informed of these risks before the surgery.