

Your Practice Online

P R E S E N T S

ACL RECONSTRUCTION - PATELLAR TENDON

Multimedia Health Education

Disclaimer

This movie is an educational resource only and should not be used to make a decision on Anterior Cruciate Ligament (ACL) Reconstruction. All decisions on ACL Reconstruction and management of ACL injury must be made in conjunction with your surgeon or a licensed healthcare provider.

Australia

Dr. Prem Lobo
G.P.O Box No. 635
Sydney NSW-2001

Phone: +61-2-8205 7549
Fax: +61-2- 9398 3818
Email: info@yourpracticeonline.com.au

USA

Holly Edmonds RN, CLNC
1006 Triple Crown Drive
Indian Trail, NC 28079

Office: 1.877.388.8569 (Toll Free)
Fax: 1.704.628.0233
E-mail: info@yourpracticeonline.net

New Zealand

Greg Eden
P O Box 17 340 Greenlane
Auckland 1130

Phone: +64-9-636 1118
Fax: +64-9-634 6282
E-mail: info@yourpracticeonline.co.nz

MULTIMEDIA HEALTH EDUCATION MANUAL

TABLE OF CONTENTS

SECTIONS	CONTENT	PAGE
1.	Normal Knee	
	a. Bones	4
	b. Fibrous Tissue	7
2.	Pathology	
	a. Injury	9
	b. Symptoms	10
	c. Diagnosis & Treatments	10
3.	ACL Reconstruction	
	a. Surgical Procedure	12
	b. Post Operative	15
4.	Conclusion	16

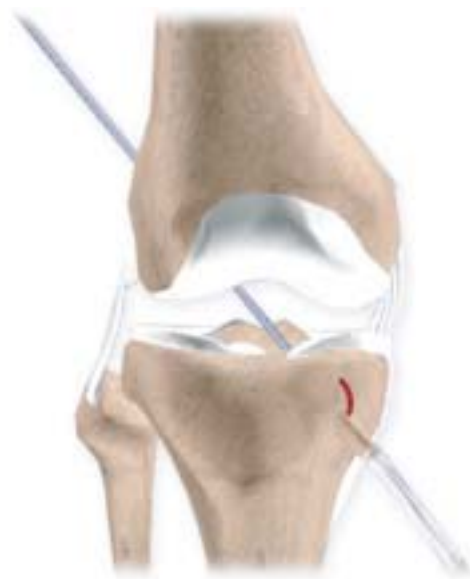INTRODUCTION

"Doc, I fell and twisted my knee. I heard a pop. It hurt briefly." This could be a ligament tear or rupture.

Ligaments are tough, non-stretchable fibers that hold your bones together. But when you injure a ligament, you may feel as though your knees will not allow you to move or even hold you up.

The knee, comprised of the femur, tibia, and patella, is a compound joint capable of movement in multiple planes. The articulation of the femur and tibia permits flexion, extension, and a small amount of rotation.

A complex array of ligaments provides stability to the knee joint during these movements. Although not specifically part of the knee joint itself, the articulation of the tibia and fibula also allows for a slight degree of movement providing an element of flexibility in response to the actions of muscles attaching to the fibula.



Section: 1

NORMAL KNEE

a. Bones

Femur

The femur (thighbone) is the largest and the strongest bone in the body. It is the weight bearing bone of the thigh. It provides attachment to most of the muscles of the knee.

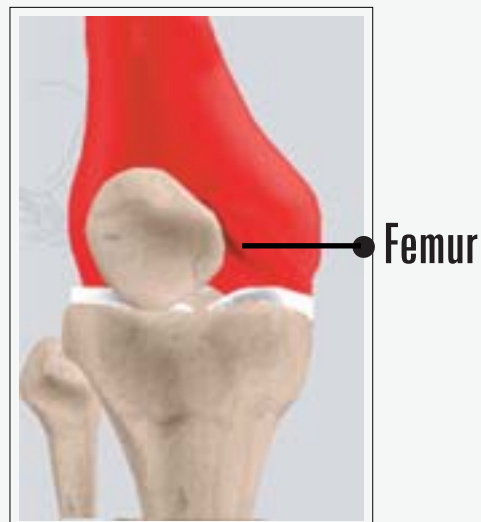
(Refer fig. 1)

Condyle

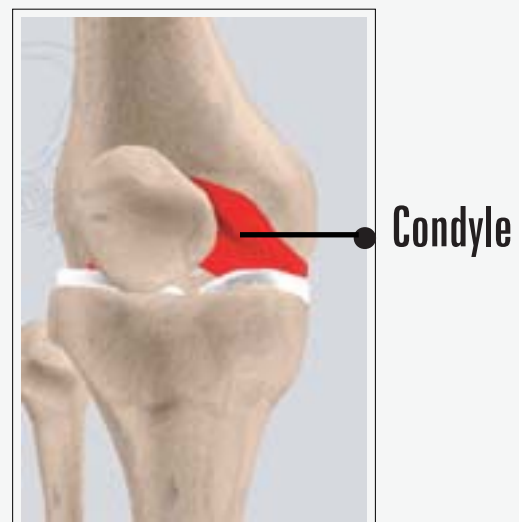The two femoral condyles make up for the rounded end of the femur. Its smooth articular surface allows the femur to move easily over the tibial (shinbone) meniscus. *(Refer fig. 2)*

Tibia

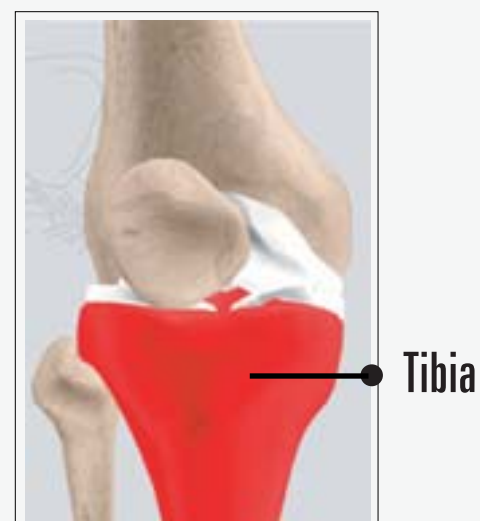The tibia (shinbone), the second largest bone in the body, is the weight bearing bone of the leg. The menisci incompletely cover the superior surface of the tibia where it articulates with the femur. The menisci act as shock absorbers, protecting the articular surface of the tibia as well as assisting in rotation of the knee. *(Refer fig. 3)*



(Fig. 1)



(Fig. 2)



(Fig. 3)

Fibula

The fibula, although not a weight bearing bone, provides attachment sites for the Lateral collateral ligaments (LCL) and the biceps femoris tendon.

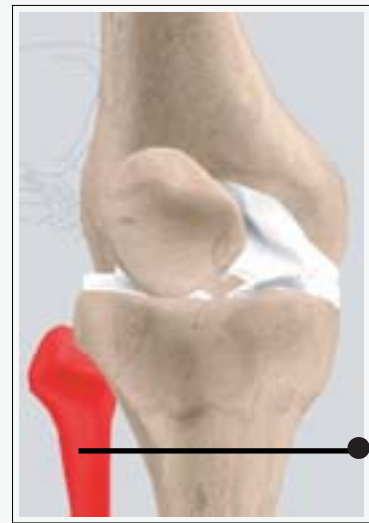The articulation of the tibia and fibula also allows a slight degree of movement, providing an element of flexibility in response to the actions of muscles attaching to the fibula.

(Refer fig. 4)

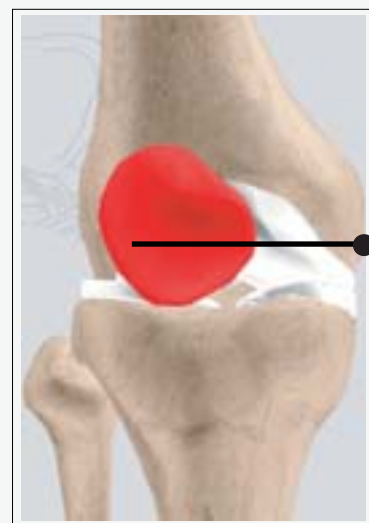Patella

The patella (kneecap), attached to the quadriceps tendon above and the patellar ligament below, rests against the anterior articular surface of the lower end of the femur and protects the knee joint. The patella acts as a fulcrum for the quadriceps by holding the quadriceps tendon off the lower end of the femur.

(Refer fig. 5)



(Fig. 4)



(Fig. 5)

Fibula

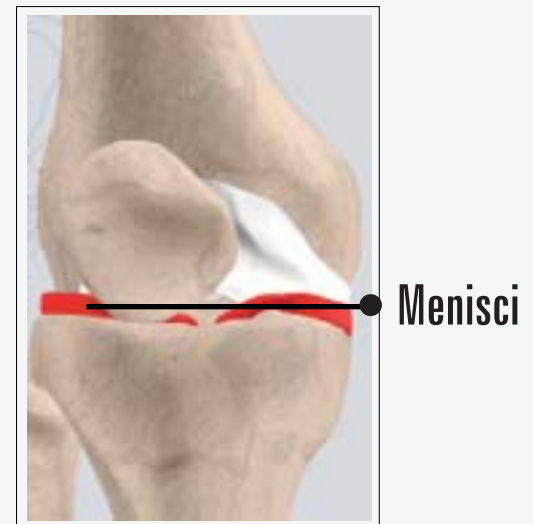Patella

Menisci

The medial and the lateral meniscus are thin C-shaped layers of fibrocartilage, incompletely covering the surface of the tibia where it articulates with the femur. The majority of the meniscus has no blood supply and for that reason, when damaged, the meniscus is unable to undergo the normal healing process that occurs in the rest of the body.

In addition, a meniscus begins to deteriorate with age, often developing degenerative tears. Typically, when the meniscus is damaged, the torn pieces begin to move in an abnormal fashion inside the joint.

The menisci act as shock absorbers protecting the articular surface of the tibia as well as assisting in rotation of the knee. As secondary stabilizers, the intact menisci interact with the stabilizing function of the ligaments and are most effective when the surrounding ligaments are intact. *(Refer fig. 6)*



(Fig. 6)

b. Fibrous Tissue

Anterior Cruciate Ligament (ACL)

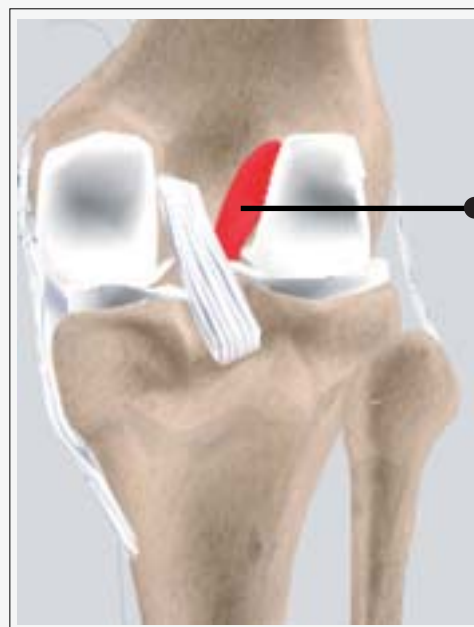The anterior cruciate ligament (ACL) is the major stabilizing ligament of the knee. The ACL is located in the center of the knee joint and runs from the femur (thigh bone) to the tibia (shin bone), through the center of the knee. The ACL prevents the femur from sliding backwards on the tibia (or the tibia sliding forwards on the femur).

Together with the posterior cruciate ligament (PCL), ACL stabilizes the knee in a rotational fashion. Thus, if one of these ligaments is significantly damaged, the knee will be unstable when planting the foot of the injured extremity and pivoting, causing the knee to buckle and give way.

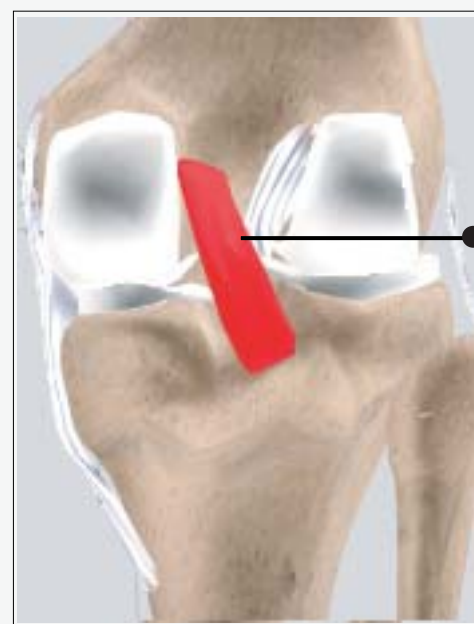(Refer fig. 7)

Posterior Cruciate Ligament (PCL)

Much less research has been done on the posterior cruciate ligament (PCL) because it is injured far less often than the ACL. *(Refer fig. 8)*



(Fig. 7)



(Fig. 8)

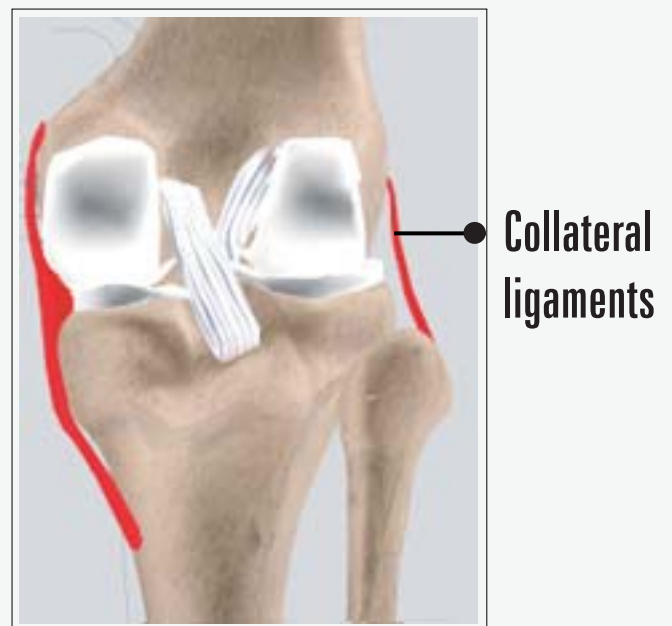
The PCL prevents the femur from moving too far forward over the tibia. The PCL is the knee's basic stabilizer and is almost twice as strong as the ACL. It provides a central axis about which the knee rotates.

Collateral Ligaments

Collateral Ligaments prevent hyperextension, adduction, and abduction

- **Superficial MCL (Medial Collateral Ligament)** connects the medial epicondyle of the femur to the medial condyle of the tibia and resists valgus force.
- **Deep MCL (Medial Collateral Ligament)** connects the medial epicondyle of the femur with the medial meniscus.
- **LCL (Lateral Collateral Ligament)** entirely separate from the articular capsule, connects the lateral epicondyle of the femur to the head of the fibula and resists varus force.

(Refer fig. 9)



(Fig. 9)

Section: 2

PATHOLOGY

a. Injury and Symptoms

The major cause of injury to the ACL is sports related. This injury occurs when the knee is forcefully twisted or hyper extended. Usually the tearing of the ACL occurs with a sudden directional change with the foot fixed on the ground or when a deceleration force crosses the knee.

The ACL can be injured in several ways:

- **Changing direction rapidly**
(Refer fig. 10)
- **Slowing down when running** (Refer fig. 11)
- **Landing from a jump**
(Refer fig. 12)
- **Direct contact, such as in a football tackle.** (Refer fig. 13)

Symptom

Many patients recall hearing a loud pop when the ligament tears, and feel the knee buckle.



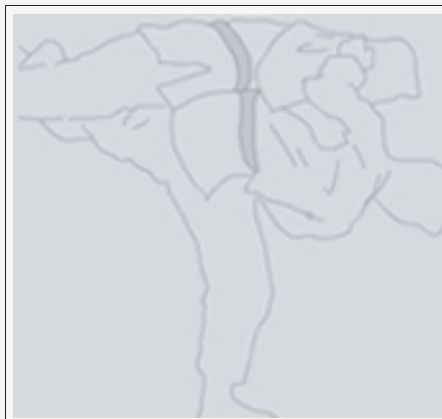
(Fig. 10)



(Fig. 11)



(Fig. 12)



(Fig. 13)

There is a rapid onset of swelling within the first two hours, and patients usually complain of a buckling sensation in the knee during twisting movements (e.g. attempting to change direction).

The symptoms following a tear of the ACL are variable. Usually there is swelling of the knee within a short time following the injury due to bleeding into the knee joint from torn blood vessels in the ligament.

Symptom

- The instability caused by the torn ligament leads to a feeling of insecurity and giving way of the knee, especially when trying to change direction on the knee.
- The pain and swelling from the initial injury will usually resolve after 2 to 4 weeks, but the instability remains. The symptom of instability and the inability for the patient to trust the knee for support is what requires treatment.

b. Diagnoses and treatment

The diagnosis of an ACL injury is usually arrived at by determining the mechanism of injury, examining the knee, determining the presence or absence of blood within the joint and performing diagnostic studies. These may include X-rays, MRI scans and stress tests of the ligament or in some cases, arthroscopic examination.

Treating ACL tears

Both conservative and operative treatment choices are available.

Conservative or non-operative treatment:

- May be used because of a patient's age or overall low activity level.
- May be recommended if the overall stability of the knee seems good. Involves a treatment program of muscle strengthening, often with the use of a brace to provide stability.

Operative treatment

- **Operative treatment (either arthroscopic or open surgery):** Uses a strip of tendon, usually taken from the patient's knee (patellar tendon) or hamstring muscle, that is passed through the inside of the joint and secured to the thighbone and shinbone.
- **Is followed by an exercise and rehabilitation program to strengthen the muscles and restore full joint mobility.**

Initial treatment

The initial treatment of an acute ACL injury often includes rest, ice, anti-inflammatory medication and physical therapy which is directed at restoring the range of motion of the injured knee.

Outcome

The torn anterior cruciate ligament represents a loss of the key guide wire of the knee. With increasing instability, the shear forces across the top of the tibia increase, the meniscal cartilages tear and the articular cartilage erodes.

Patients who do not participate in pivoting sports or do not require knee stability for daily chores and work may attempt a rehabilitation program to strengthen leg muscles and also wear a brace for pivoting activities. Patients who are young, participate in pivoting sports and require knee stability for work should undergo ACL reconstruction. A torn ACL makes the knee vulnerable to re-injury because it is not stable in certain activities.

Successful ACL reconstruction surgery tightens your knee and restores its stability. It also helps you avoid further injury and get back to playing sports.

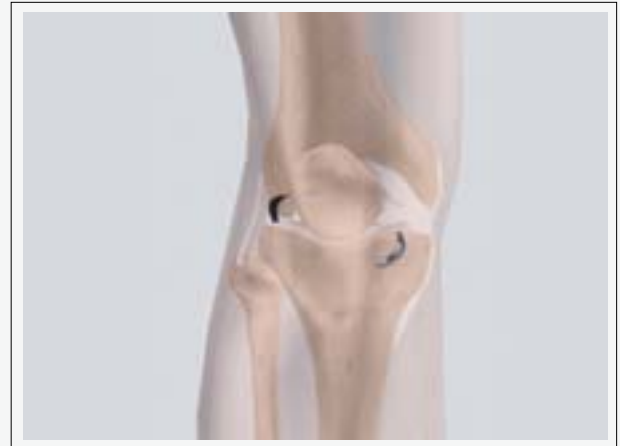Also important in the decisions about treatment is the growing realization by Surgeons that long term instability may lead to early arthritis of the knee.

Section: 3

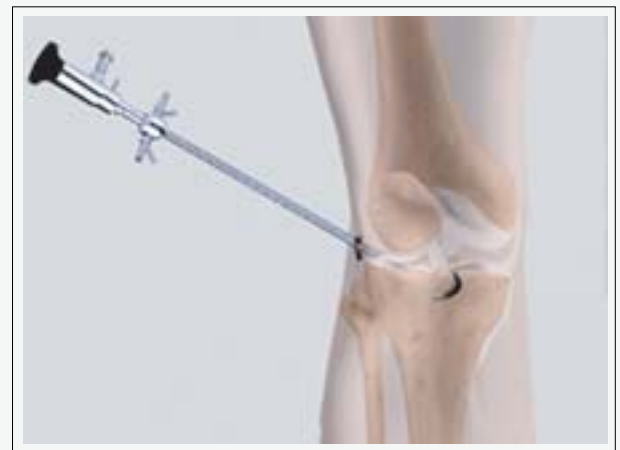ACL RECONSTRUCTION

a. Surgical Procedure

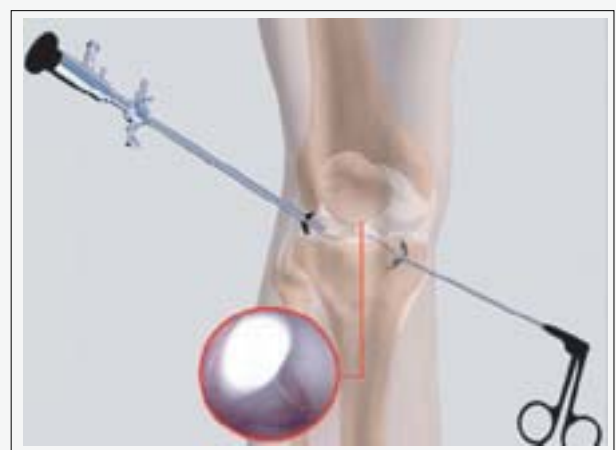- The surgeon makes two small incisions (about $\frac{1}{4}$ of an inch) around the joint area. Each incision is called a portal. (Refer fig. 14)
- In one portal, the arthroscope is inserted to view the knee joint. Along with the arthroscope, a sterile solution is pumped to the joint which expands the knee joint giving the surgeon a clear view and room to work. (Refer fig. 15)
- With the images from the arthroscope as a guide the surgeon can look for any pathology or anomaly. The large image on the television screen allows the surgeon to see the joint directly and to determine the extent of the injuries, and then perform the particular surgical procedure, if necessary. (Refer fig. 16)
- The torn pieces of the ACL are resected and the pathway for the new ACL is prepared.



(Fig. 14)

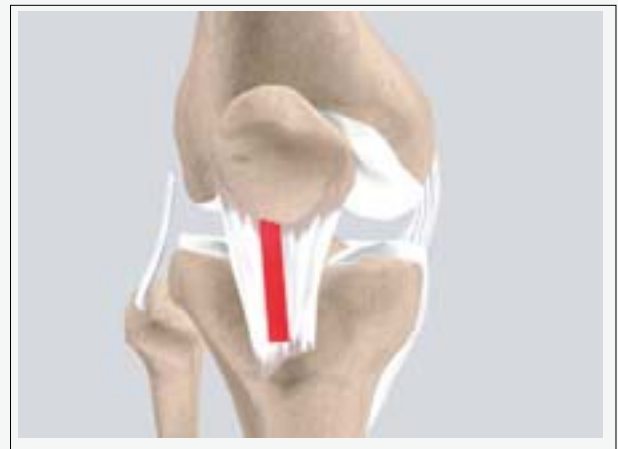

(Fig. 15)

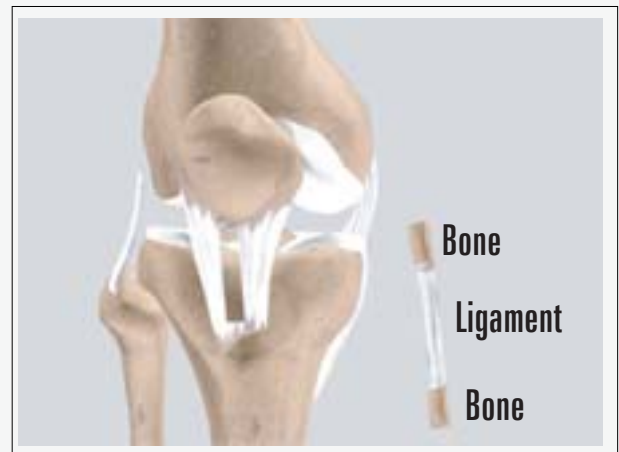


(Fig. 16)

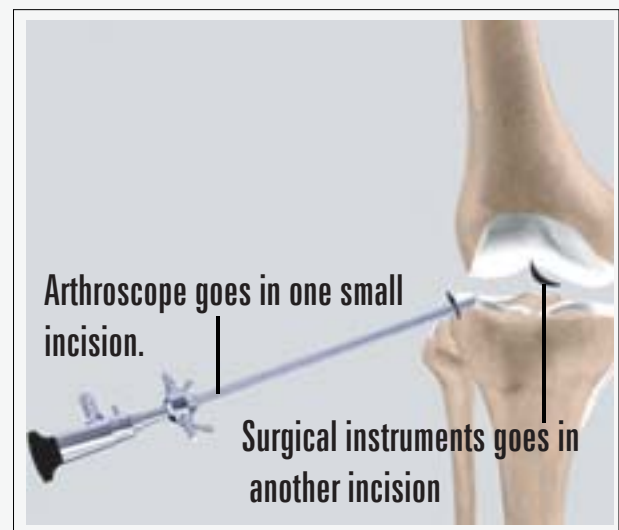
- An incision is made over the patellar tendon and the middle third of the tendon identified. *(Refer fig. 17)*
- The middle third of the patellar tendon together with its bone attachment on each end is harvested and prepared. *(Refer fig. 18)*
- The remaining portions of the patellar tendon on either side of the graft are re-approximated (sutured) after its removal. The incision is closed.
- The arthroscope is reinserted into the knee joint and the rest of the surgery continues arthroscopically. *(Refer fig. 19)*
- A guide wire is drilled in the femoral bone entering the femur at the ACL femoral origin.
- A drill is placed over the guide wire and a hole equal to the new ACL size is drilled through the femur. *(Refer fig. 20)*



(Fig. 17)

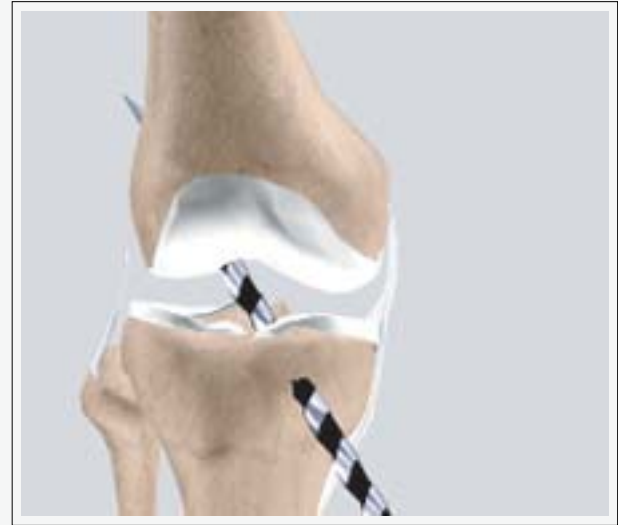

(Fig. 18)

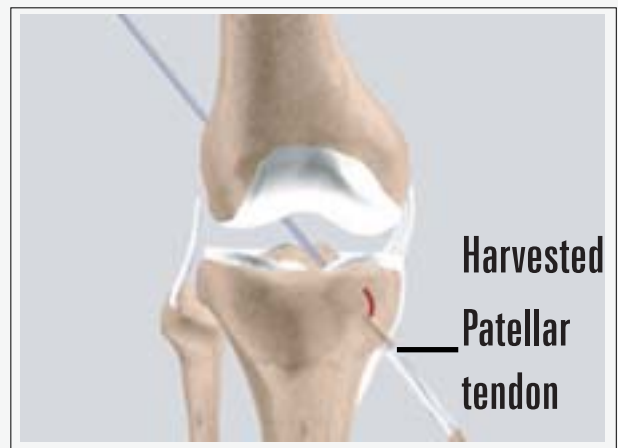

(Fig. 19)

- A stitch is connected from the bone to a guide wire and this is pulled through the predrilled holes in the tibia and femur. (Refer fig. 21)
- A screw is then placed in the femur. The graft is then tensioned and a second screw is placed in the tibia to secure the new ACL to the surrounding bone.
- After reconstructing the ACL, the portals (incisions) are closed by suturing or by tape.



(Fig. 20)



(Fig. 21)

b. Post Operative

Post operative recovery is dependant on regular physiotherapy and you will be given instructions on what exercises to do and how often to do them. In general, return to competitive sports is not permitted for 5-6 months to give time to the new ACL graft to incorporate into the knee joint.

A good knowledge of this procedure will make the stress of undertaking the operation easier for you to bear.

The decision to proceed with the surgery is made because the advantages of surgery outweigh the potential disadvantages. It is important that you are informed of these risks before the surgery.

You must not proceed until you are confident that you understand this procedure, particularly the complications.

Conclusion

We hope that you have found this information helpful. We also trust you will know that if any of the material mentioned in this booklet is confusing or hard to understand, your surgeon will be glad to address your concerns either by phone or on your next visit to the clinic.

Thank you for taking the time to read this material. We understand that this manual contains a great deal of information. We also know that the best results come from the most informed patients and those motivated to see themselves in their best condition as quickly as possible.

Surgery exists as a method of correcting a problem and improving a patient's condition which is everyone's goal. Please be assured that your surgeon and the medical team are more than willing at any time to answer any questions or to review any material before and after surgery. The best results are obtained when people are provided the right information to become informed, motivated, and confident.

Your ACL RECONSTRUCTION Team